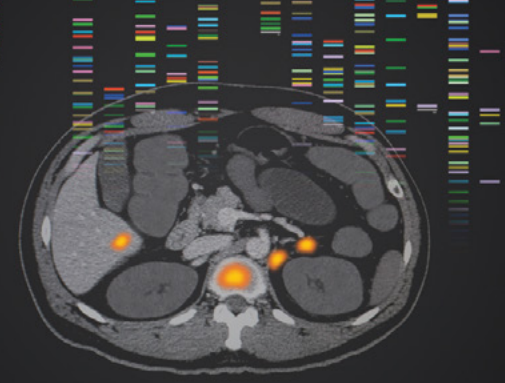


PHENOTYPIC BIOMARKERS MAY SIMPLIFY THE APPROACH TO PRECISION MEDICINE IN ADVANCED PROSTATE CANCER¹⁻³



pre-ci-sion med-i-cine

[/pré'siZHən/ \ 'me-di-sən]

An approach that utilizes diagnostic tools to select therapies for appropriate patients with the goal of **optimizing outcomes** and **minimizing adverse events**.⁴

The complexity of advanced prostate cancer (APC) makes the implementation of genotypic precision medicine challenging in various ways:

1 CLINICAL	Bone biopsies are painful, technically difficult, and challenging to interpret. ⁵⁻⁷
2 OPERATIONAL	Optimizing test selection, biopsy technique, timing, and test result interpretation is a challenge for genotypic precision medicine. ⁸⁻¹⁰
3 BIOLOGIC	The majority of clinically relevant driver mutations are present in <5% of prostate cancer tumors due to the heterogeneity of the disease. ¹¹⁻¹⁵

Taken together, these features of APC underlie the need for novel precision medicine approaches, including the use of **phenotypic biomarkers** that can be detected through noninvasive diagnostics such as prostate-specific membrane antigen positron emission tomography (PSMA PET) imaging.¹⁶⁻²⁰

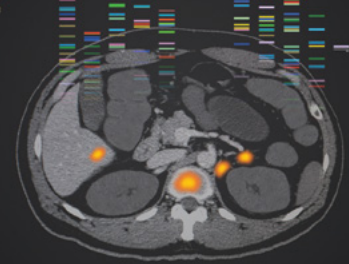
PSMA PET leverages radiotracers to visualize **PSMA-expressing** prostate cancer tissue at a high sensitivity and specificity.²¹⁻²⁴ PET imaging with radiotracers offers a phenotypic approach that may simplify the use of precision medicine in APC.^{1-3,22,24,25}

NCCN makes no warranties of any kind whatsoever regarding their content, use or application and disclaims any responsibility for their application or use in any way.

References

1. Sant GR et al. *NPJ Precis Oncol*. 2017;1(1):21.
2. Seyhan AA, Carini C. *J Transl Med*. 2019;17:114.
3. Aronson SJ, Rehm HL. *Nature*. 2015;526(7573):336-342.
4. Jameson J et al. In: *Harrison's Principles of Internal Medicine*. 20th ed. New York, NY: McGraw-Hill Education; 2018:1-20.
5. Friedlander TW et al. *Am Soc Clin Oncol Educ Book*. 2017;37:358-369.
6. Łukaszewski B et al. *Contemp Oncol (Pozn)*. 2017;21(2):98-103.
7. Ross RW et al. *Clin Cancer Res*. 2005;11(22):8109-8113.
8. Ersek JL et al. *Am Soc Clin Oncol Educ Book*. 2018;38:188-196.
9. Levitt LA et al. *J Oncol Pract*. 2019;15(6):325-329.
10. Giri VN et al. *J Clin Oncol*. 2020;38:2798-2811.
11. Armenia J et al. *Nat Genet*. 2018;50(5):645-651.
12. Magi-Galluzzi C et al. *Mod Pathol*. 1997;10(8):839-845.
13. Li L et al. *Sci Signal*. 2015;7(326):ra47.
14. Visakorpi T et al. *Nat Genet*. 1995;9(4):401-406.
15. Koivisto P et al. *Cancer Res*. 1997;57:314-319.
16. Kulkarni HR et al. *Br J Radiol*. 2018;91:20180308.
17. Abou D et al. *Front Oncol*. 2020;10:884.
18. Rowe SP et al. *J Nucl Med*. 2015;56(7):1003-1010.
19. Osborne JR et al. *J Urol*. 2014;191(5):1439-1445.
20. Kratochwil C et al. *J Nucl Med*. 2016;57:1170-1176.
21. Referenced with permission from the NCCN Clinical Practice Guidelines in Oncology (NCCN Guidelines[®]) for Prostate Cancer V.2.2021. © National Comprehensive Cancer Network, Inc. 2021. All rights reserved. Accessed March 2, 2021. To view the most recent and complete version of the guideline, go online to NCCN.org.
22. Hofman MS et al. *Lancet*. 2020;395(10231):1208-1216.
23. Perara M et al. *Eur Urol*. 2016;70(6):926-937.
24. Calais J et al. *Lancet Oncol*. 2019;20(9):1286-1294.
25. Müller J et al. *Eur J Nucl Med Mol Imaging*. 2019;46(4):889-900.

PSMA IS A DIAGNOSTIC, PROGNOSTIC, AND CLINICALLY RELEVANT BIOMARKER IN ADVANCED PROSTATE CANCER¹⁻³



PSMA expression is an example of a **phenotypic trait**, which is defined as an observable characteristic that is produced through the interaction of a genotype and environment.^{4,5} Phenotypes can be detected through PET imaging, among other modalities.⁶

PSMA has been shown to have potential utility at multiple time points within the prostate cancer care spectrum^{1-3,7}:



Diagnosis

Compared with conventional imaging, PSMA PET/CT (computed tomography) was 27% (95% CI 23-31) more accurate (92% [88-95] vs 65% [60-69]; $P < 0.0001$) for the detection of prostate cancer among patients with high-risk localized disease.^{1*}



Prognosis

PSMA expression level was negatively correlated with 5-year recurrence-free survival (88.2% for no expression vs 26.8% for high expression).^{2†}




Clinical Management

PSMA PET/CT results after conventional imaging may have led to management changes in up to 60% of patients.^{3,7‡}

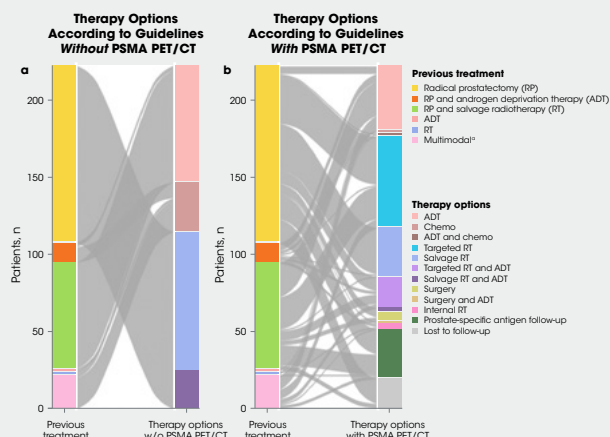
PSMA is overexpressed in

>80%

of men with prostate cancer^{2,8,9}



PSMA PET/CT may help guide clinical management with a tailored approach^{3‡}



‡Multimodal included surgery, salvage RT, ADT, and/or chemotherapy combined.³ Reproduced by permission from Springer Nature: *Eur J Nucl Med Mol Imaging*, Müller J et al. Copyright 2019.

PSMA is a diagnostic and potential therapeutic target that may enable a phenotypic precision medicine approach to managing APC.¹⁻³

*The ProPSMA study was a prospective, multicenter, randomized, controlled trial of men with high-risk, apparently localized prostate cancer. Three hundred two were randomly assigned to receive either CT and bone scan (conventional imaging) or PSMA PET/CT. First-line imaging was done within 21 days of randomization. The primary end point was accuracy of first-line imaging for identifying either pelvic nodal or distant metastatic disease defined by the receiver-operating curve using a predefined reference standard including histopathology, imaging, and biochemistry at 6-month follow-up. Results for subgroups of patients with pelvic nodal (area under the curve 91% vs 59% [32% absolute difference; 28-35]) and distant (95% vs 74% [22% absolute difference; 18-26]) metastases also showed superiority of PSMA PET/CT.¹

†PSMA expression was assessed in a retrospective study by immunohistochemistry in 294 preoperative biopsies, 621 primary tumor foci from 242 radical prostatectomies, 43 locally advanced or recurrent tumors obtained from transurethral prostate resection, 34 lymph node metastases, 78 distant metastases, and 52 benign prostatic samples from patients who underwent surgery. PSMA expression was categorized as no expression (score of 0), low expression (1), medium expression (2), or high expression (3). Expression was correlated with recurrence-free survival as the primary end point measure. Disease recurrence was defined as biochemical recurrence (prostate-specific antigen [PSA] increase above the postoperative nadir following radical prostatectomy) and recurrence-free survival was used as the primary end point for survival analysis.²

‡The aim of the retrospective, real-world, single-institution study from Switzerland was to assess the effect of PSMA PET/CT on management and outcome in all patients imaged during the first year after its introduction into clinical routine. The rate of detection of recurrence was based on clinical reports. In the 203 patients with follow-up 6 months after PSMA PET/CT, the therapies effectively implemented as well as follow-up PSA levels were evaluated, with a PSA value of <0.2 ng/mL representing a complete response and a decrease in PSA value of at least 50% from baseline representing a partial response.³

References

- Hofman MS et al. *Lancet*. 2020;395(10231):1208-1216.
- Hupe MC et al. *Front Oncol*. 2018;8:623.
- Müller J et al. *Eur J Nucl Med Mol Imaging*. 2019;46(4):889-900.
- Phenotype. Merriam-Webster. <https://www.merriam-webster.com/dictionary/phenotype>. Accessed September 9, 2020.
- Sant GR et al. *NPJ Precis Oncol*. 2017;1(1):21.
- Kratochwil C et al. *J Nucl Med*. 2016;57:1170-1176.
- Calais J et al. *J Nucl Med*. 2018;59(3):434-441.
- Hope TA et al. *J Nucl Med*. 2017;58(12):1956-1961.
- Pomykala KL et al. *J Nucl Med*. 2020;61(3):405-411.